


# RETINA PANEL

Suggestions and Considerations  
for Retina Referrals

SEC 2023



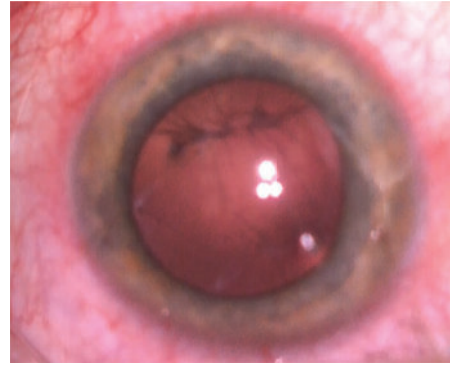
## OVERVIEW

- Case-based roundtable covering:
- Cataract complications
- Diabetes
- Uveitis
- Trauma
- Inherited retinal disorder

## CATARACT COMPLICATION

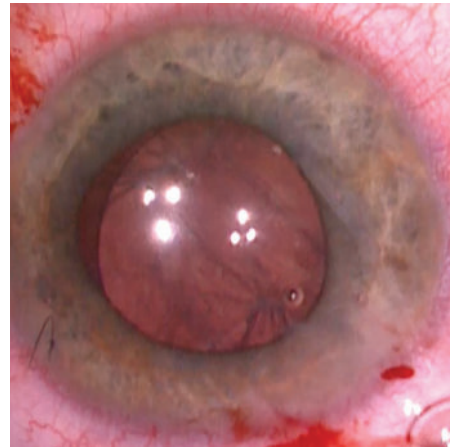
---

58yo F presenting with a  
posterior capsular rent



## DISCUSSION

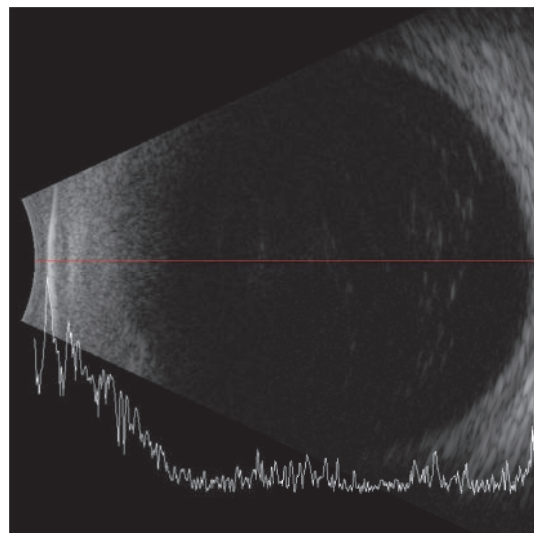
- Timing of referral / intervention?
- What are you looking for on exam?
- Preoperative planning?
- Intraoperative considerations?
- Postoperative considerations



## CATARACT COMPLICATION

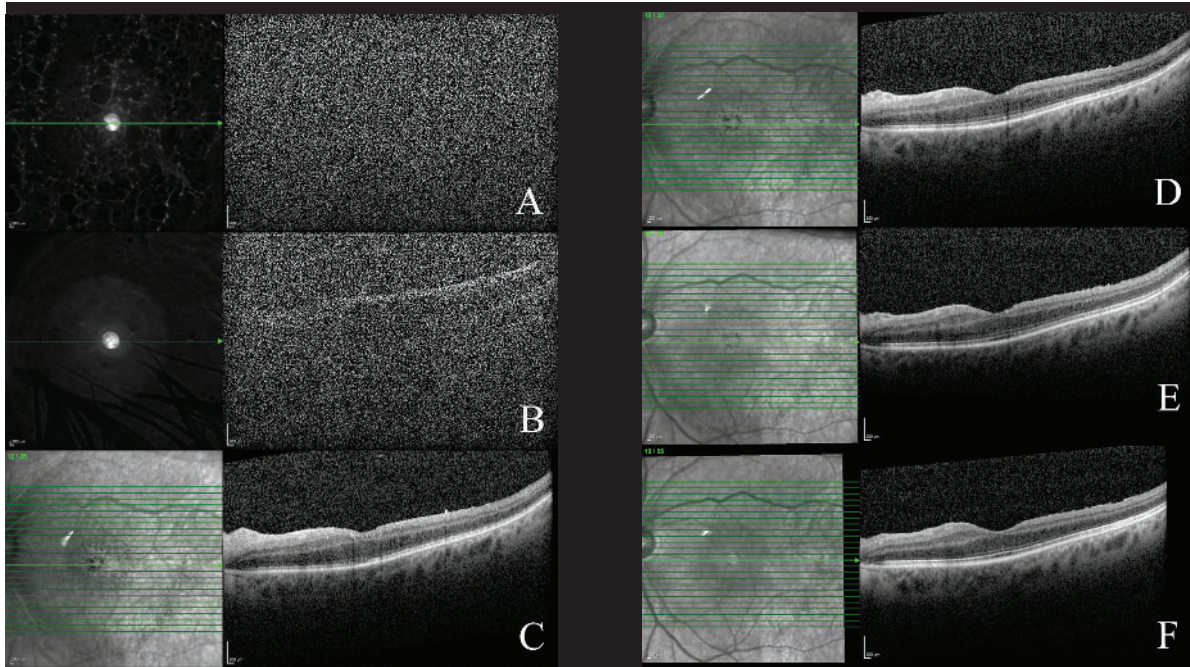
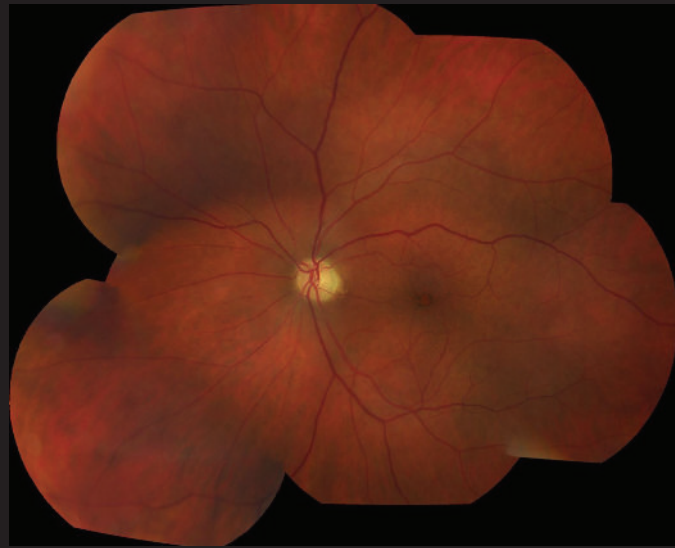---

54yo M s/p CE/IOL for  
traumatic cataract



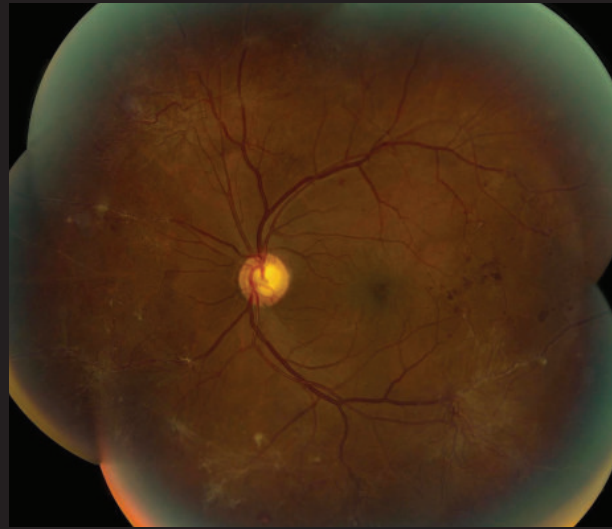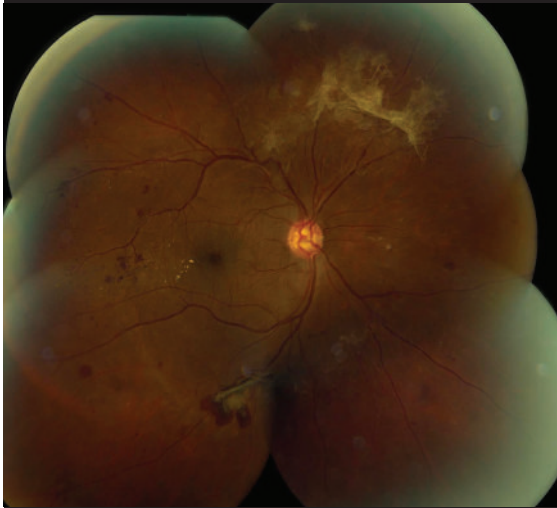## DISCUSSION

- Next steps?
- Intraoperative considerations?
- Postoperative care and follow-up?



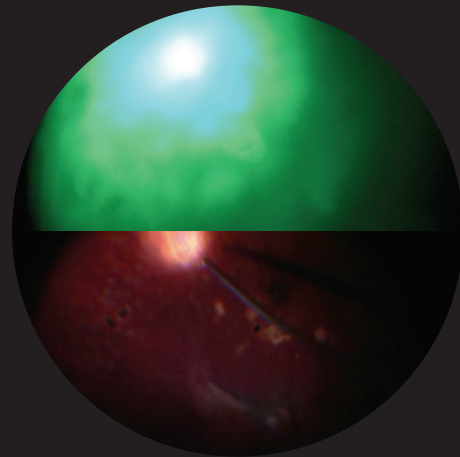
DIABETIC PATIENT

30yo pregnant female  
with new floaters



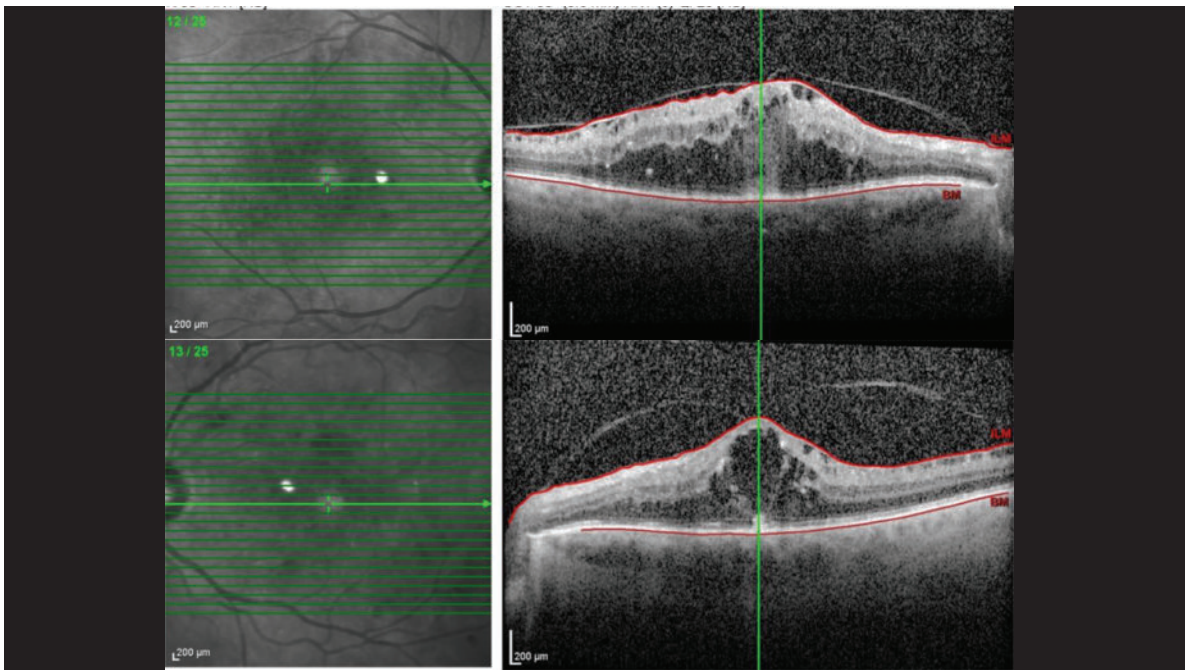
## DISCUSSION

- Timing of referral?
- Any treatment prior to referral?
- Treatment plan?
- PRP?
- Periocular/intraocular steroids?
- PPV?
- What if they develop VH or TRD?



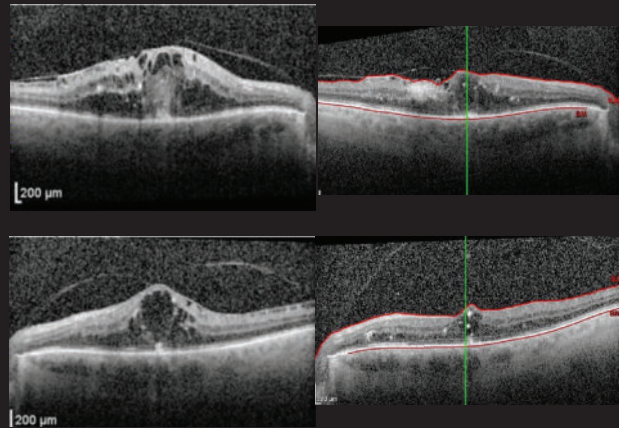
DIABETIC PATIENT

64yo male for cataract  
clearance



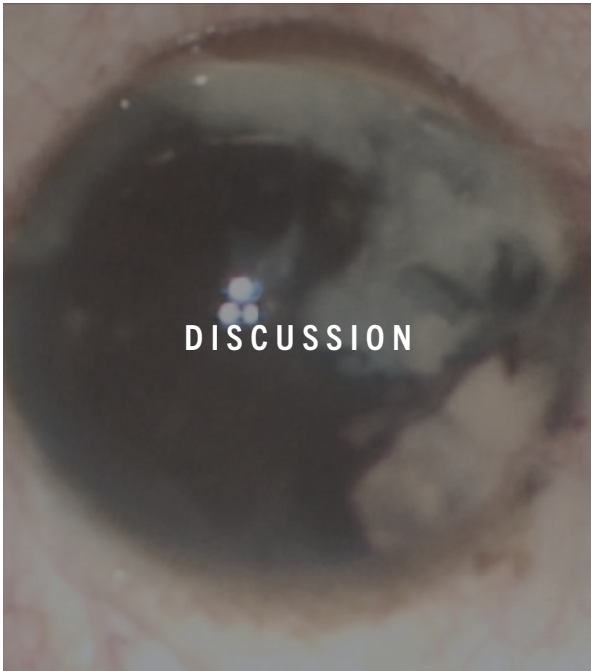
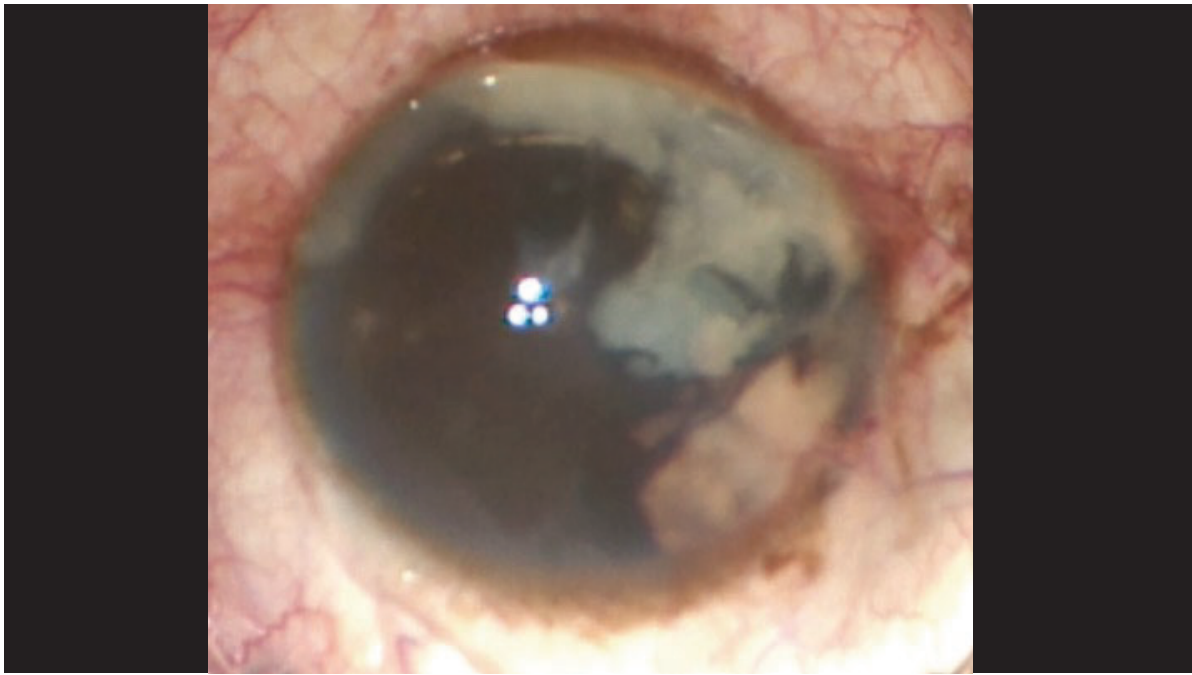## DISCUSSION

- Timing of referral?
- What if patient needs cataract surgery?
- Timing of cataract surgery and injections?
- Do you tell them to wait few days between injections?



## UVEITIS

42yo M with h/o of  
open globe s/p repair  
with worsening  
intraocular  
inflammation and  
ciliary body mass

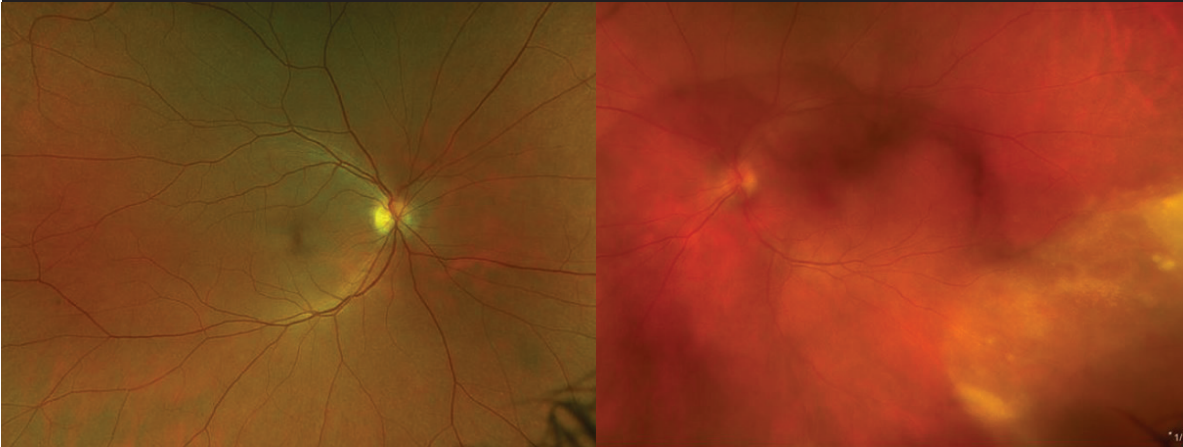


- Important examination findings?
- Testing?
- Biopsy?
- Antibiotics?
- Timing of intervention?
- Intervention?

**SURGICAL VIDEO (3 MIN)**

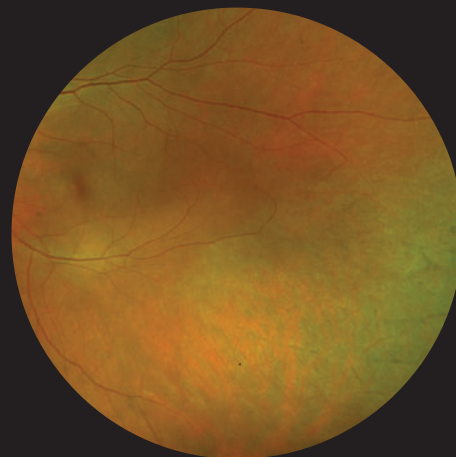
# UVEITIS

49yo F with new floaters OS



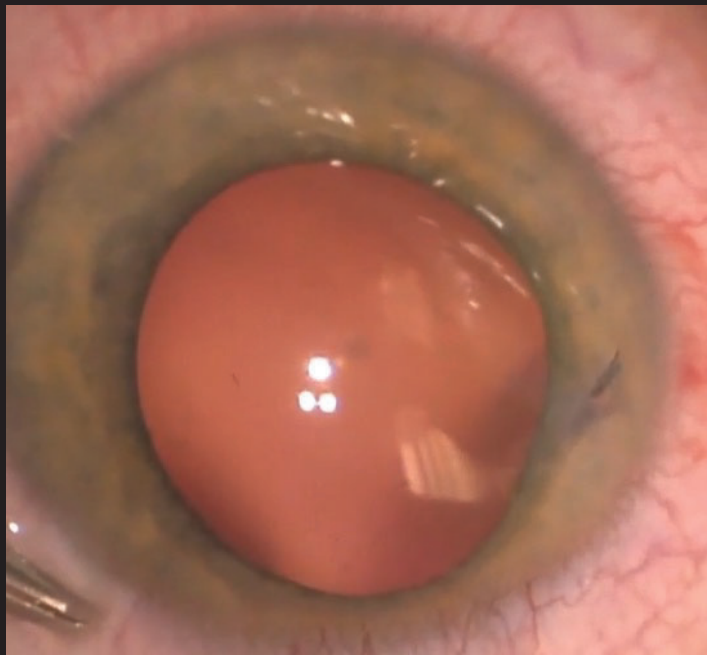
## DISCUSSION

- Timing of referral?
- Workup?
- Treatment?
- Follow-up?



**TRAUMA**

14yo M, felt a pop  
while playing with  
his mechanical  
pencil in class

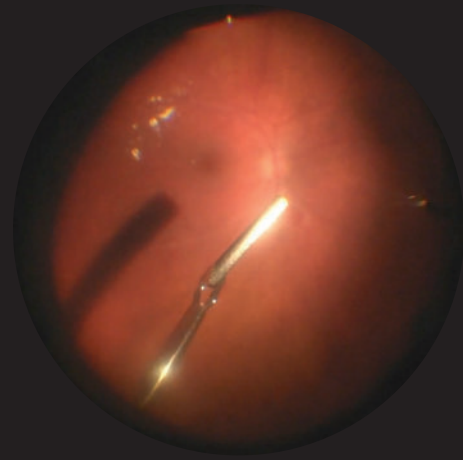


**IOFB VIDEO (3MIN)**



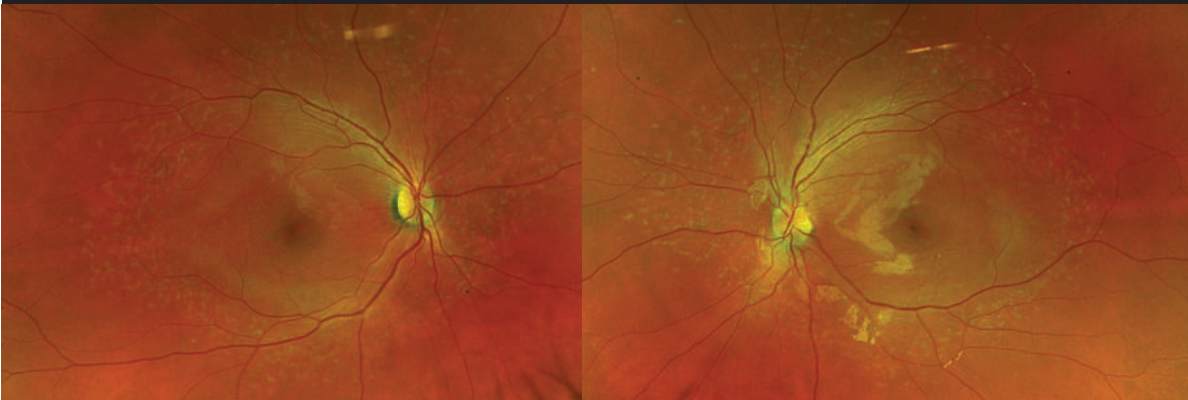
## DISCUSSION

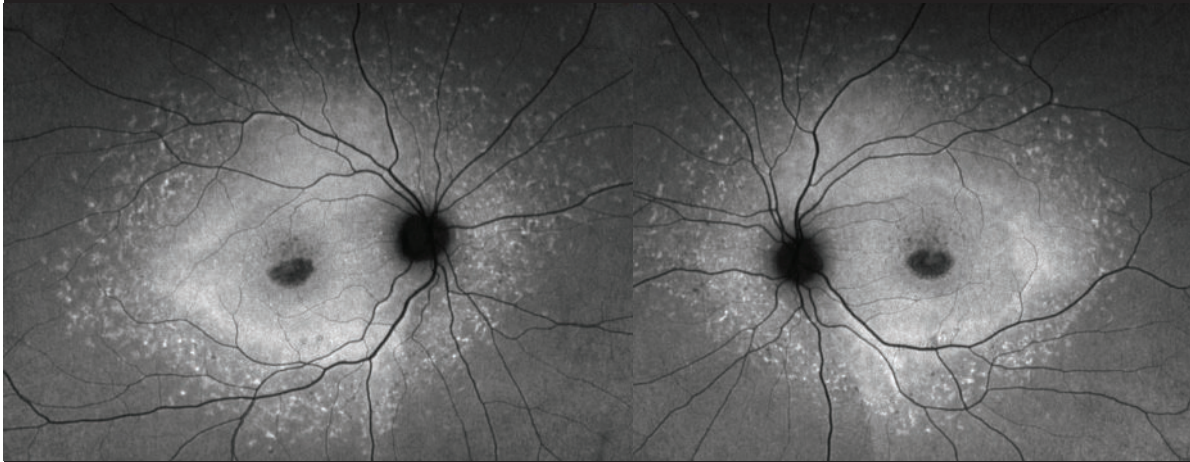
- Preoperative considerations?
- Operative considerations?
- Postoperative considerations?



DECREASED  
VISION

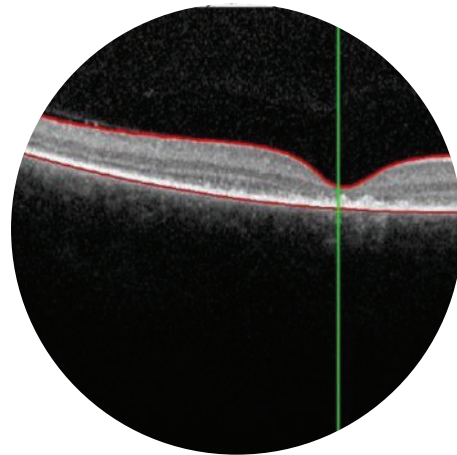
11yo F presenting  
for 3<sup>rd</sup> opinion for  
unknown retinal  
condition





## DISCUSSION

- Testing?
- Follow-up?
- Referrals?



### RESULT: POTENTIALLY POSITIVE

Two Pathogenic variants identified in ABCA4. ABCA4 is associated with autosomal recessive inherited retinal disorders.

GENE	VARIANT	ZYGOSITY	VARIANT CLASSIFICATION
ABCA4	c.2915C>A (p.Thr972Asn)	heterozygous	PATHOGENIC
ABCA4	c.4139C>T (p.Pro1380Leu)	heterozygous	PATHOGENIC

#### About this test

This diagnostic test evaluates 330 gene(s) for variants (genetic changes) that are associated with genetic disorders. Diagnostic genetic testing, when combined with family history and other medical results, may provide information to clarify individual risk, support a clinical diagnosis, and assist with the development of a personalized treatment and management strategy.

GENE THERAPY PPV VIDEO(1MIN)

